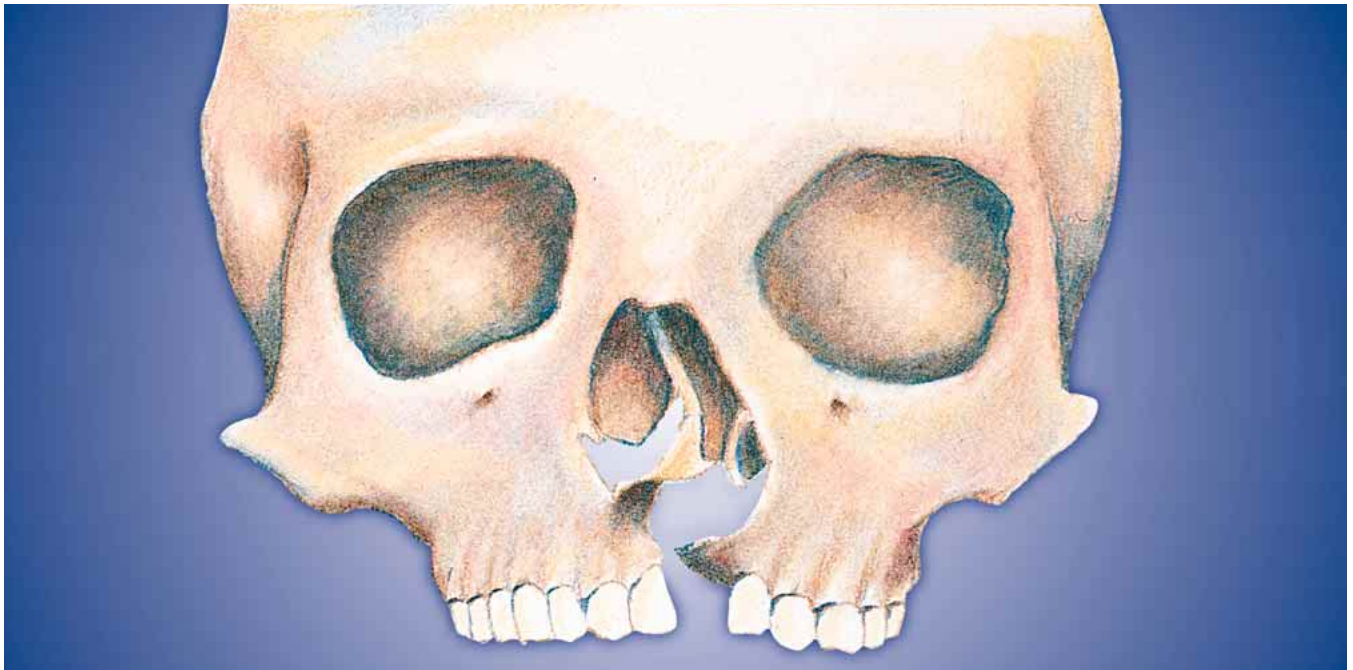


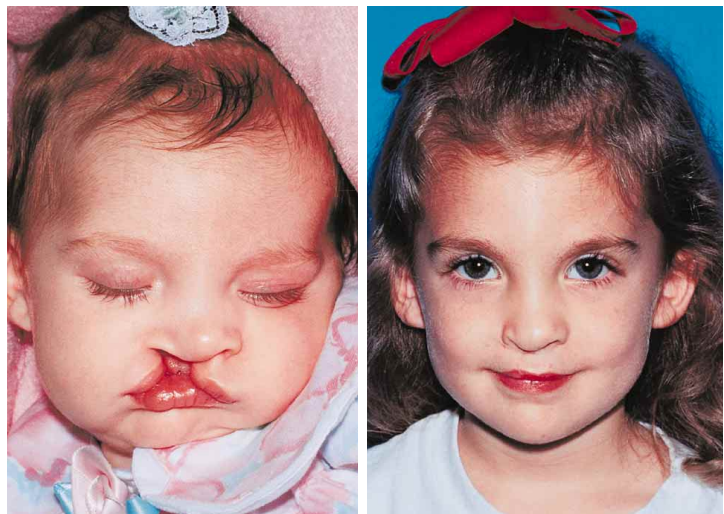Clefts of the Lip and Palate



CLEFTS OF THE LIP AND PALATE

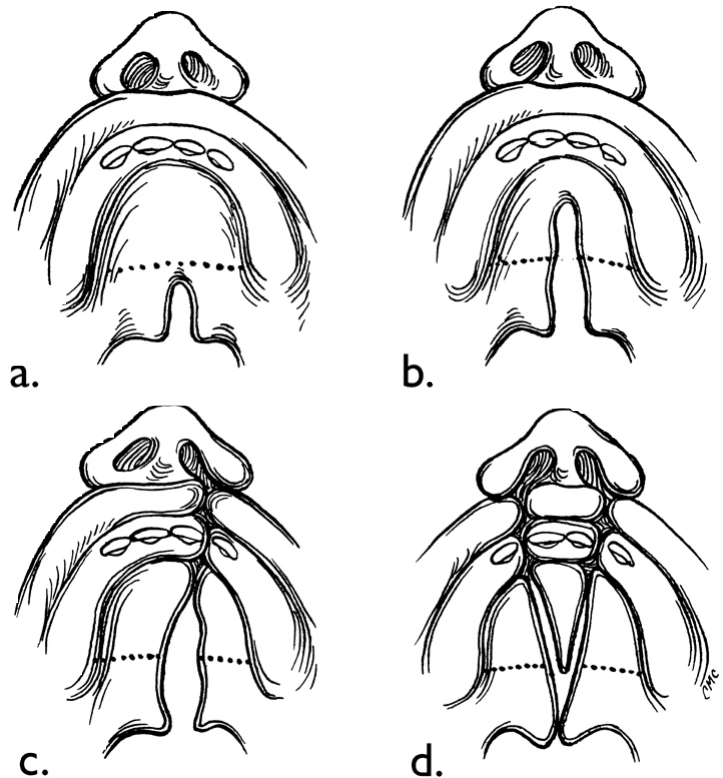
Each year approximately 227,500 or 7 percent of births in the United States are affected by birth defects of the head and face. The most common of these are clefts of the lip and palate which occur once in every 700 births. Clefts occur in infants of all races with a 2:1 male to female ratio. The incidence of clefts is highest in the Asian population and lowest in African Americans. Of all orofacial clefts, 21 percent present as cleft lip only (unilateral and bilateral), 46 percent present as cleft lip and palate, while the remaining 33 percent have cleft palate alone.

What is a cleft? A cleft is a division or separation of parts of the lip or roof of the mouth that is formed during the early months of development of the unborn child. All of the parts of the lip or roof of the mouth are present; they simply failed to fuse in a normal way. Surgical intervention is necessary to align the parts and join them. Often the bones of upper jaw (maxilla) and/or the upper gum are affected. A cleft lip can be incomplete with a variable degree of notching of the lip, or complete, extending through the lip and into the nose.



Preoperative

Postoperative



Variations in clefts of the palate.

A). Cleft of soft palate only. **B).** Incomplete cleft of soft and hard palate. **C).** Complete unilateral cleft palate. **D).** Complete bilateral cleft palate.

Clefts of the palate can vary in severity. Some may involve just the uvula and the soft palate. These are incomplete clefts of the palate. Others extend the length of the palate and are complete clefts. They may involve one side of the palate (unilateral) or both sides (bilateral).

Etiology: The exact cause of lip and palatal clefting is not known, but most experts feel that it is due to both genetic and environmental factors. Clefts are associated with abnormalities in the genes which may be a result of inheritance or from a spontaneous mutation during fetal development. We recommend genetics counseling to discuss causes of the cleft and the recurrence risk factors.

Team Assessment: Children born with clefts should be carefully assessed by the craniofacial team in order to detect potentially serious abnormalities that can be associated with clefting. There are over 150 syndromes that include cleft lip or palate in their differential diagnosis. Generally, clefting is the only congenital abnormality that the child has, but nearly 15 percent of all cleft lip or palate patients present clinically with multiple problems.

The team concept allows a systematic, comprehensive treatment plan to be developed and allows the team members to work together to identify problems before they become significant. The most common specialties involved in the care of a child with a cleft are: plastic surgery, otolaryngology, dentistry, audiology, speech pathology, genetics and pediatrics. Once a complete assessment of the child with a cleft has been performed, a plan for treatment can be outlined.

FEEDING AN INFANT WITH A CLEFT

Feeding an infant is important not only in providing nourishment, it also provides an intimacy and closeness for both the parent and the child. Infants with a cleft of the lip or of the soft palate seldom have problems with feeding either by bottle or breast.

In babies with clefts of the hard palate, the opening in the roof of the mouth often causes difficulty in creating adequate pressure on the nipple, thus creating an inability to suck well enough to get adequate nourishment. Feeding the infant takes patience and practice. At our center we recommend the use of a soft squeezable plastic bottle like Mead Johnson with an orthodontic nipple such as Nuk. You can increase the flow by gently squeezing or putting pressure on the bottle. It is important to feed the infant before he/she becomes too hungry. Position the infant in an upright position with the head tilted back slightly. This position allows the milk to flow down into the throat and less into the nose. Infants with clefts do swallow more air and need to be burped more frequently. At first, it may take extra time, but this will steadily decrease. Feeding time of the newborn varies from 20-30 minutes. When feeding takes longer than 45 minutes, the infant may be burning up calories necessary to gain weight. If this occurs the feeding consultant should be contacted to help with the feeding technique.

Breast feeding the newborn with a cleft of the hard palate is often unsuccessful. Generally the infant cannot produce enough negative pressure to obtain ample breast milk to provide adequate nourishment. Using a breast pump to extract the milk and feeding the infant breast milk from a squeezable bottle is recommended.

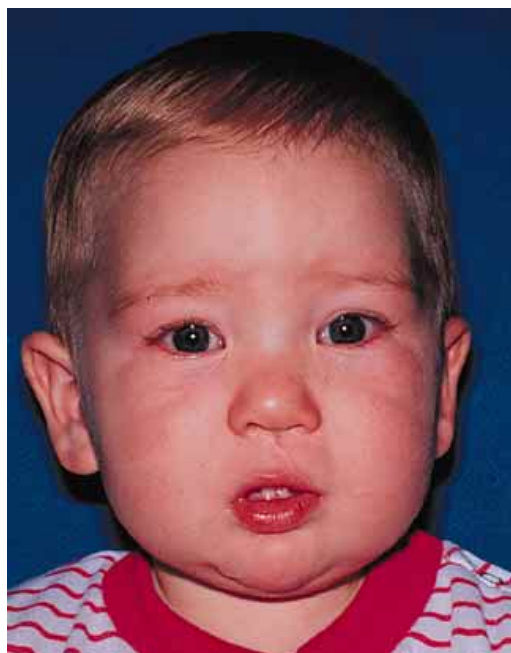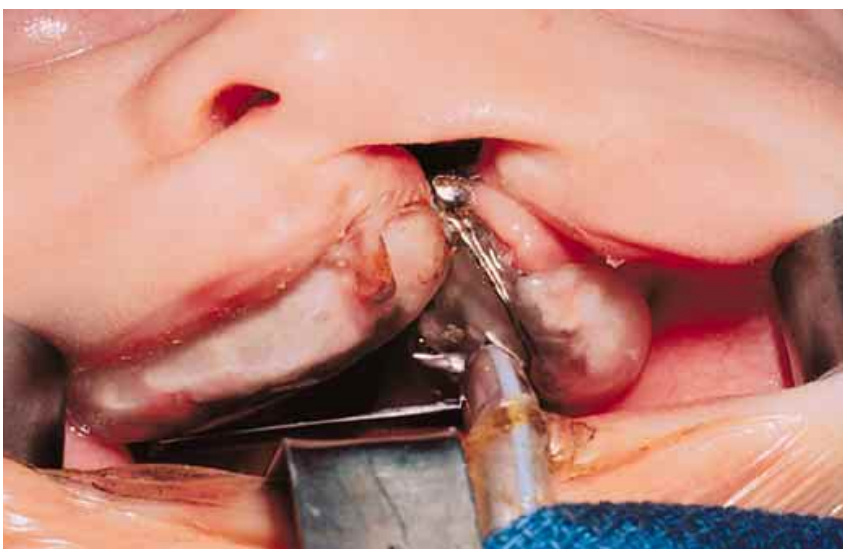
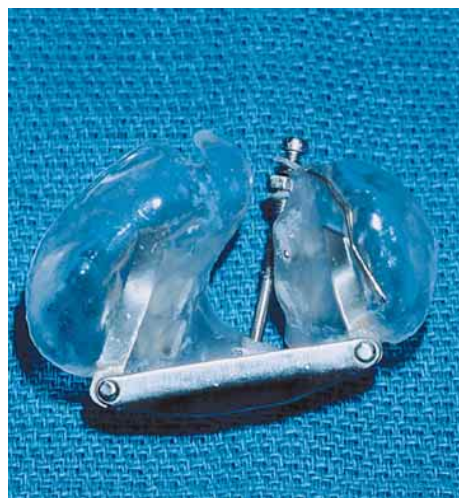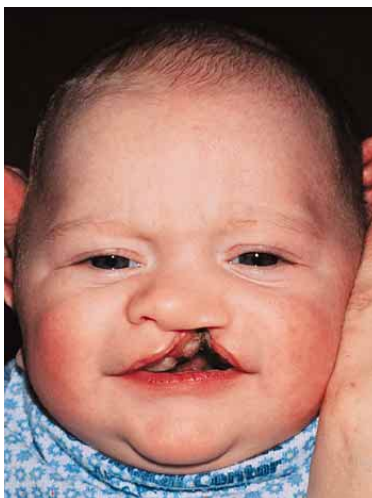SURGERY

Cleft Lip Repair - The objective in repairing the lip is to close the cleft to create a pleasing face that will develop normally with minimal scarring. Closure of the lip is performed by the plastic surgeon when the baby is approximately 3 months of age and weighs at least 10 pounds. When there is involvement of the alveolus and palate, an orthodontic appliance may be placed in the maxillary segments as the first procedure. This is performed by the team dentist as an outpatient surgical procedure. The appliance is used to align the alveolus so that it can be repaired (gingivoperiosteoplasty) at the time of the lip repair or lip adhesion. This improves nasal support on the cleft side and creates a tunnel that should develop bone, closing the cleft. If the alveolus is not closed in infancy, then the alveolar ridges will be orthodontically aligned and a bone graft performed to stabilize the maxilla (5-10 years of age). Correction of the nasal deformity is usually performed at the time of lip repair. Additional procedures may be necessary to enhance the appearance of either the lip or nose.

Photos to the right:

A unilateral cleft lip is shown. A custom fitted Latham appliance has been fabricated and placed to rotate alveolar segments together. Postoperative result is shown after repair of alveolar cleft and lip.

Unilateral Cleft Lip with Custom Latham



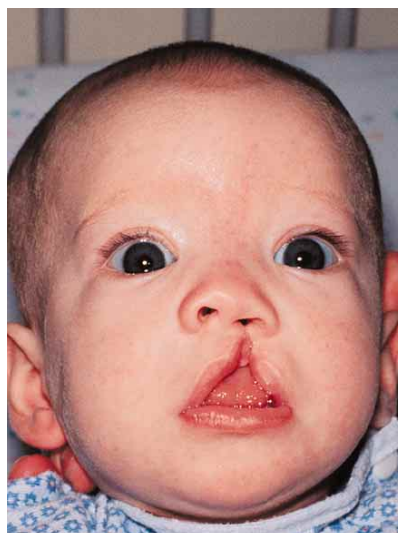
UNILATERAL CLEFT LIP REPAIR

A unilateral cleft lip results from failure of the union of the maxillary and median nasal processes, thus creating a split or cleft in the lip on either the left or right side. It may be just a notching of the lip or extend completely through the lip into the nose and palate. A number of procedures have been described to repair the unilateral cleft lip. The procedure used at our Center is the Millard rotation advancement technique. The procedure is designed to reconstruct the lip, muscle, oral mucosa, and to reposition the nose. It is performed under general anesthesia with surgery lasting 2-3 hours and a hospital stay of 2-4 days. Special considerations are necessary for feeding and positioning the infant postoperatively. The baby's elbows are restrained from bending to prevent him/her from disrupting the nose or lip. Positioning the child in an infant seat keeps him/her from rolling over and injuring the lip or nose. Pacifiers and nipples are not allowed. The baby is fed with a special syringe feeder with a soft tube. It takes approximately 3 weeks for the wound to gain enough strength to discontinue the above precautions. The lip scar is initially red and swollen, but it begins to mature and improve in appearance in six-twelve months.

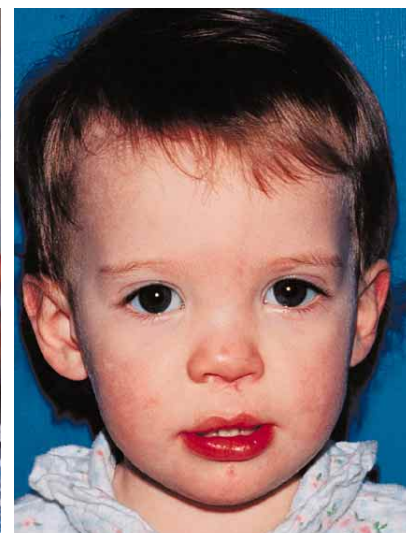Photos to the right:

Photos of infants who underwent repair of unilateral cleft lip with rotation advancement technique.

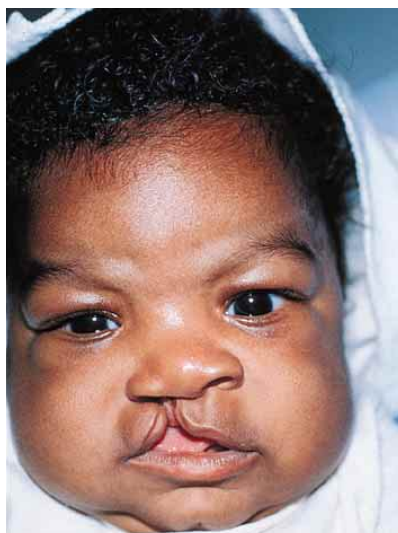Unilateral Cleft Lip



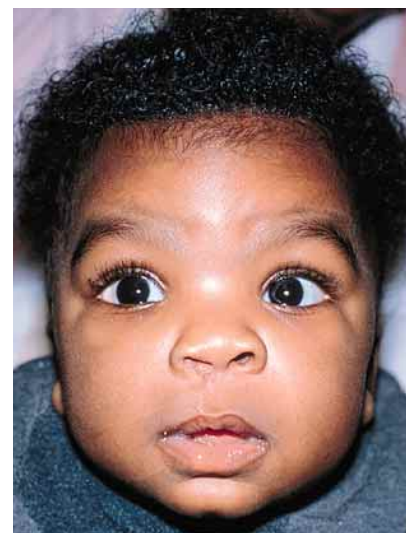Preoperative



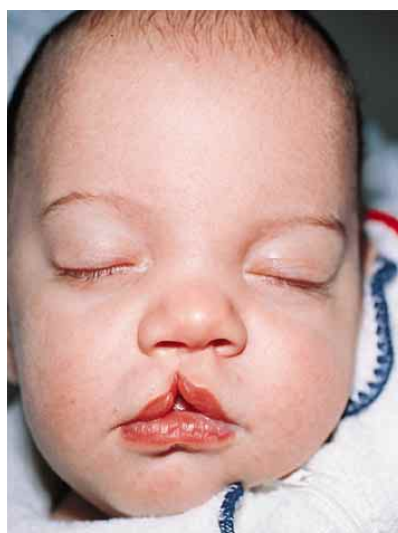Postoperative



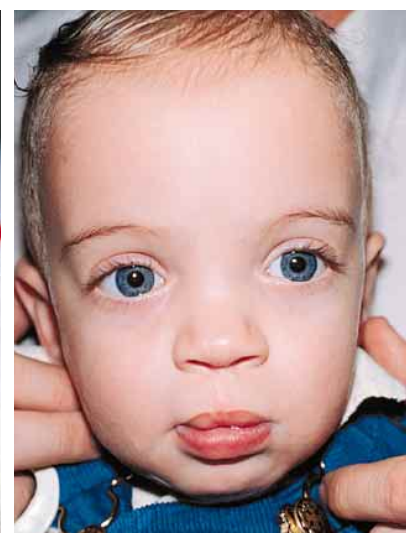Preoperative



Postoperative



Preoperative

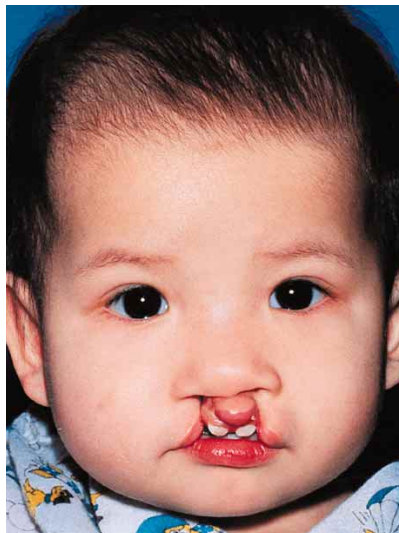

Postoperative

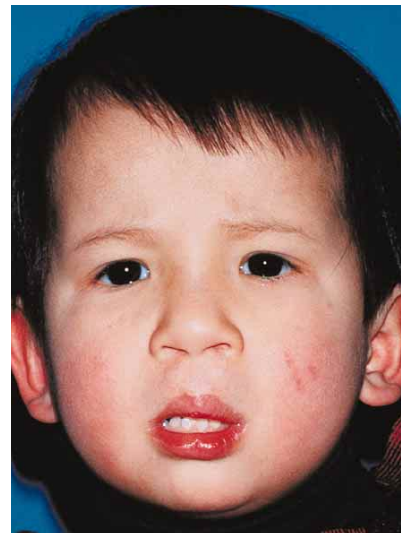BILATERAL CLEFT LIP

The bilateral cleft lip involves separation of the lip along philtral lines, isolating the central segment (prolabium). Fifteen percent of children born with cleft lips have bilateral clefts. The associated nasal deformity is usually more severe than the unilateral cleft due to a very short columella and flaring of both nostrils. Surgical correction of the bilateral cleft lip is usually performed in one procedure at three months of age; however, the procedure may be staged, closing one cleft at a time. Rotation of the nostrils to a more normal position is performed in the first procedure. A second procedure is performed by 2-3 years of age to lengthen the columella. Patients with complete bilateral cleft lips frequently require additional procedures to enhance the appearance of the lip and nose. Performed under general anesthesia, the operation generally requires 2-3 hours. A hospital stay of 2-4 days should be expected. Feeding, positioning and elbow restraints are the same as those for repair of the unilateral cleft lip.

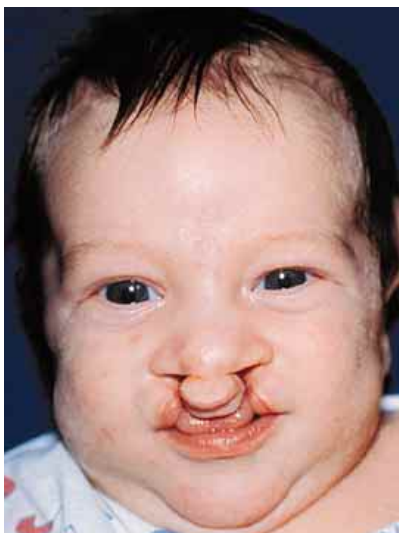Bilateral Cleft Lip



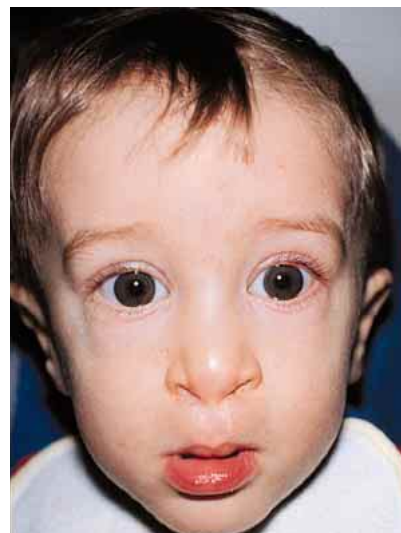Preoperative



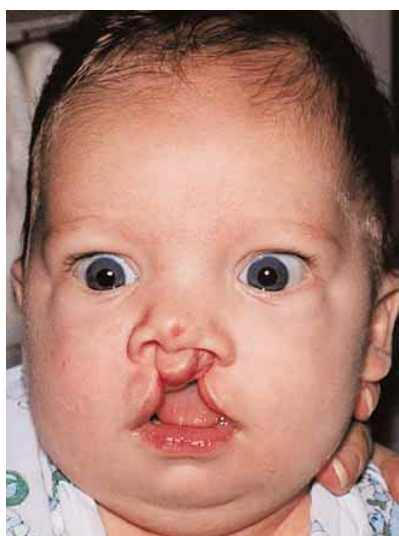Postoperative



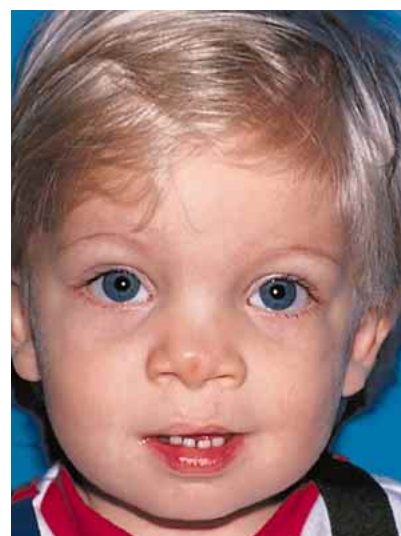Preoperative



Postoperative



Preoperative



Postoperative

Photos to the right:

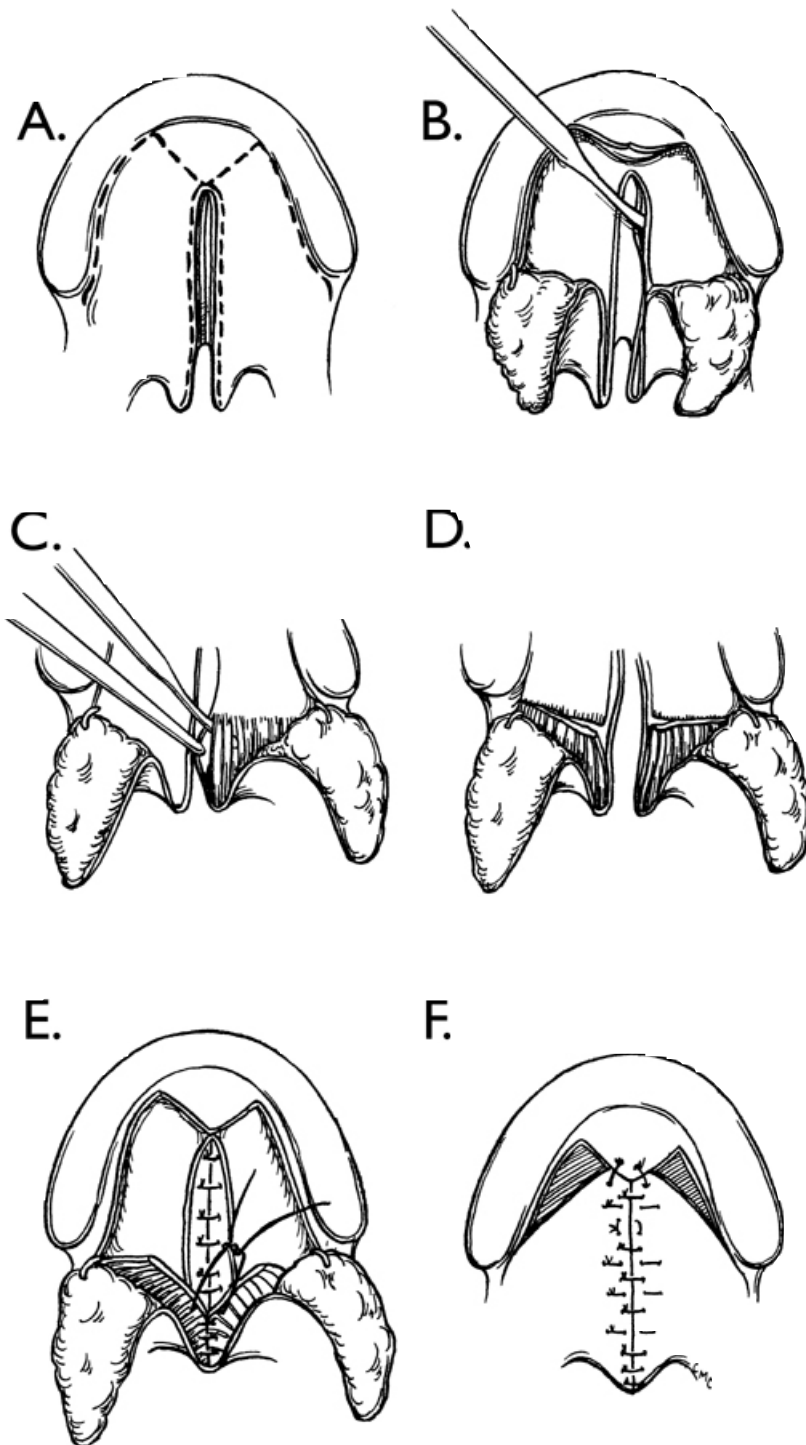
Photos of infants who underwent one stage repair of bilateral cleft lip.

CLEFT PALATE REPAIR

The objective of cleft palate surgery is to close the palate to restore normal function to eating and drinking and to enhance the development of normal speech.

Clefts of the palate can occur as isolated deformities or in combination with a cleft of the lip. Cleft palates result from failure of fusion of the embryonic facial processes resulting in a fissure through the palate. This may be complete (extending through the hard and soft palates) or any degree of incomplete (partial cleft). The palate forms the roof of the oral cavity and the floor of the nose; thus, a cleft causes a free communication between these two cavities. As a result, treatment of palatal clefts is complex because of potential problems with feeding, speech, middle ear infections, occlusion and jaw alignment.

Surgical treatment of the cleft palate is best accomplished in one surgical procedure before the child reaches 12-14 months of age. The cleft palate is surgically closed by elevating two muscoperiosteal flaps. The levator muscles are elevated, redirected and repaired; and a three layer closure of nasal mucosa, muscle and oral mucosa accomplished. Surgery under general anesthesia usually lasts about 2 hours. Special precautions as those after the repair of the cleft lip are necessary for 2-3 weeks. We prefer that the child be weaned from the bottle and pacifier prior to the palatal repair. No hard or crunchy foods are allowed for 3 weeks post operatively.



Cleft Palate Repair:

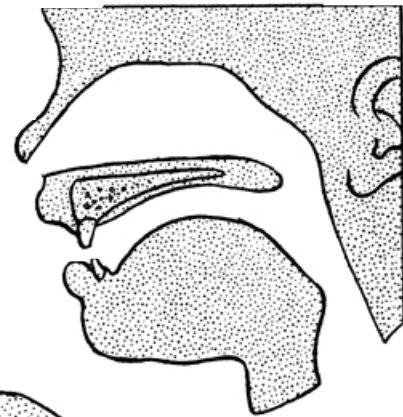Closure of cleft palate with pushback palatoplasty. A). Two muscoperiosteal flaps are outlined. B). Flaps are elevated off the hard palate. C,D). The abnormal levator muscle insertion to the hard palate is identified and cut free. E). The nasal lining is closed as a separate layer and the levator muscle reapproximated. F). The palatal mucoperiosteal flaps are closed in a V-Y fashion.

PHARYNGEAL FLAP

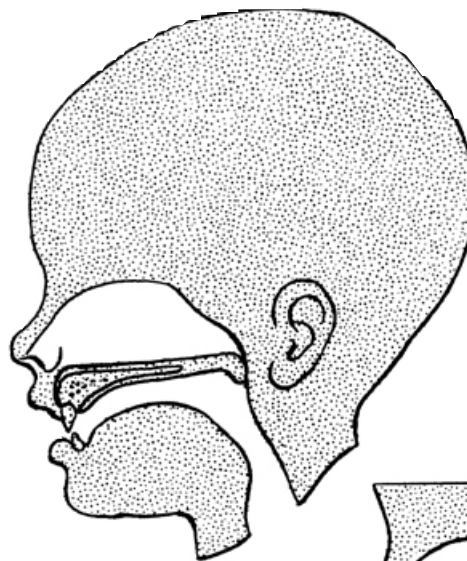
Approximately 70-80 percent of all cleft palate patients will develop velopharyngeal competence after palate closure and thus the potential for normal speech. The remaining 20-30 percent will require speech therapy and/or an additional surgical procedure called a pharyngeal flap. To correct persistent hypernasal speech, this procedure involves raising a flap of tissue from the posterior pharynx and inserting it into the soft palate. This flap is indicated when the repaired palate is too short or the muscles do not function properly, causing a persistent hypernasal speech. The procedure is performed usually after the age of 4-5 when speech and velopharyngeal competence can be thoroughly assessed and before the child begins school.

LATE CLEFT TREATMENT

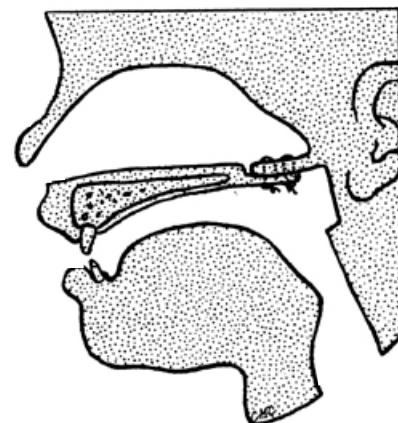
The Craniofacial Center can also help those individuals that have grown up without access to a comprehensive, coordinated team approach. For adults with speech problems, the previously mentioned pharyngeal flap, combined with an intensive regimen of speech therapy, can produce significant improvements. Orthognathic surgery is available to patients with deformities of the jaws to improve their appearance as well as to correct dental occlusion. For soft tissue revision of a severely tightened or notched upper lip, an Abbe flap is the surgical option. This procedure is usually indicated in bilateral cleft patients who have a short or deficient columella and a tightened upper lip. This operation



Inadequate Closure



Adequate Closure



Corrected Closure

Pharyngeal Flap:

The pharyngeal flap procedure for hypernasal speech. A superiorly based flap of tissue is raised from the posterior pharynx and sutured to the soft palate thereby decreasing the amount of air through the nose. Lateral ports or holes are left so that the nose will not be obstructed.

can add fullness to the upper lip as well as lengthen the columella. A number of additional surgical therapies, similar to the ones described, are available to patients who desire further improvements.

HEARING

Children with cleft palate have a higher incidence of hearing problems. The Eustachian tube connects the middle ear space to the back of the throat. It normally opens and shuts to relieve pressure that builds up behind the ear drum. If the Eustachian tube does not open, then the pressure increases until mucus or “fluid” accumulates behind the eardrum. The muscles responsible for opening the Eustachian tube do not function as well in children with cleft palates resulting in more frequent problems with fluid, otitis media and ear infections which can be very painful. Because of this problem, it is important to have the infant’s hearing tested during the first few months. If hearing is impaired by fluid buildup or unequal pressure, it may be necessary for the otolaryngologist to place pressure equalizing (PE) tubes. Tubes are often placed at the time of the lip or palate surgery. It is crucial that children with cleft palates have regular hearing tests to monitor middle ear problems that could alter the development of normal hearing as well as speech. As the child grows, the frequency of ear infections and fluid in the ears seem to decrease.

SPEECH

Speech development in children with cleft lip only should be normal. The unrepaired cleft palate causes speech to sound hypernasal because air passes through the nose while talking. Most speech sounds require the nose to be closed off from the mouth. Cleft palate surgery usually remedies the problem, but speech therapy is still recommended. Approximately 20-30 percent of cleft palate

patients will have velopharyngeal incompetence or hypernasal speech after surgery, and may require a pharyngeal flap to correct it around the age of 4-5 years.

DENTAL

Clefts of the palate generally have an effect on dental development. In the area of the cleft, teeth often erupt in a crooked position with extra teeth or missing teeth being common in the cleft area. Radiographs are often taken to determine the exact position of the teeth. Dental problems have an effect on speech, chewing, appearance and frequently require orthodontic treatment. Early orthodontic intervention may require a palatal expansion device with further alignment of the dental arches. Later treatment after the primary teeth have erupted can begin at 10-12 years of age. Orthognathic surgery may be indicated if a malocclusion develops due to abnormal growth of the maxilla.

PIERRE ROBIN SYNDROME

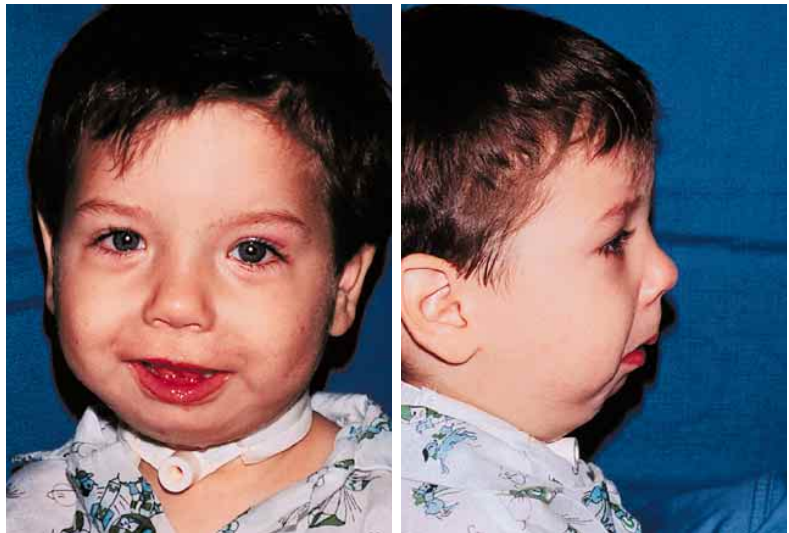This syndrome was described in 1923 by Pierre Robin in which he described airway obstruction associated with glossoptosis and hypoplasia of the mandible. Today this syndrome is characterized by retrognathia or micrognathia, glossoptosis, and airway obstruction. An incomplete cleft of the palate is associated with the syndrome in approximately 50% of these patients.

In patients with micrognathia (small jaw) or retrognathia, the chin is posteriorly displaced causing the tongue to fall backward toward the posterior pharyngeal wall. This results in obstruction of the airway on inspiration. Crying or straining by these children can often keep the airway open. However, when the child relaxes or falls asleep, airway obstruction occurs. Due to these respiratory problems, feeding may become very difficult. This can lead to

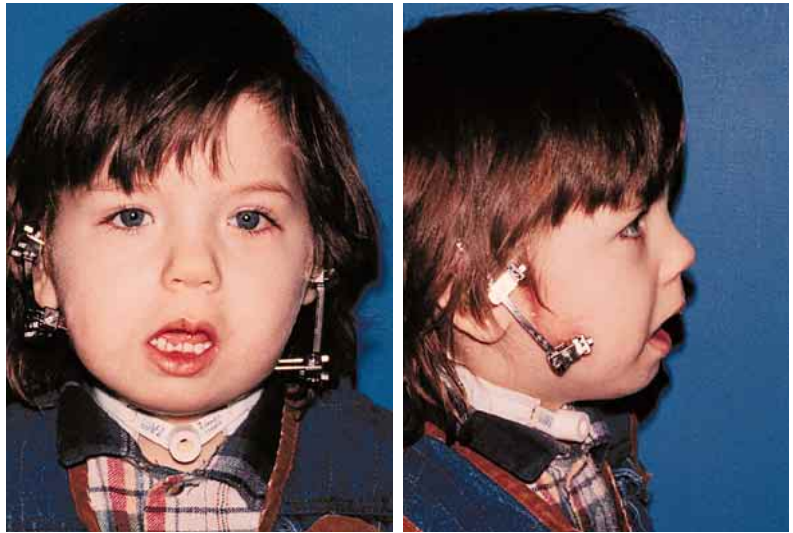a sequence of events: glossoptosis, airway obstruction, crying or straining with increased energy expenditure and decreased oral intake. This vicious cycle of events if untreated can lead to exhaustion, cardiac failure, and ultimately death.

Treatment of this syndrome can be divided into conservative therapy versus surgical intervention. The majority of these patients can be managed by placing the infant in the prone position until adequate growth of the jaw occurs. This causes the jaw and the tongue to fall forward opening the airway. If this type of treatment fails the infant should then be considered for a tongue-lip adhesion (a procedure to pull the tongue forward) or a tracheostomy.

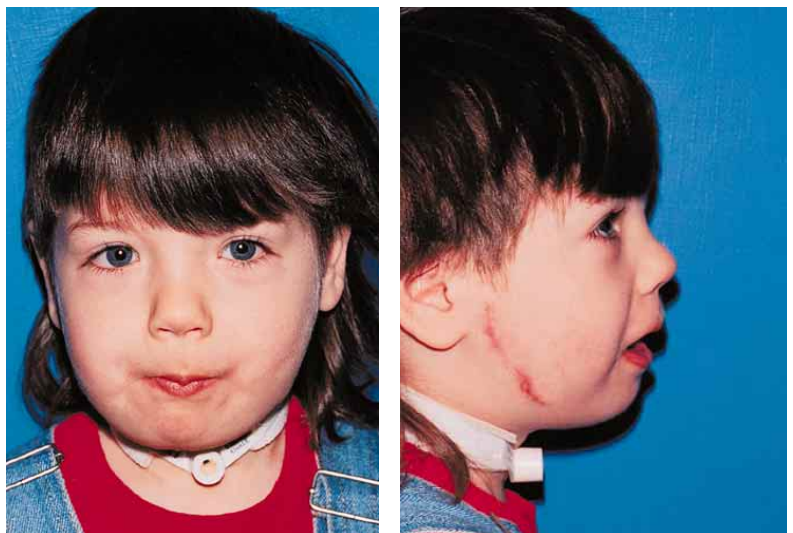In children with severe underdevelopment of the lower jaw, a new technique called mandibular bone expansion is now available. This technique also called distraction osteogenesis involves placement of an expansion device that is turned daily to slowly lengthen the jaw. An external incision is required to make a surgical cut through the jaw bone with placement of pins that are secured to the expansion device. Once the amount of expansion of the bone has been obtained (4-5 weeks) the device is then kept in place until the bone gap heals with new bone formation (8 weeks). This technique can be performed at a very early age which is a significant advantage over the traditional technique of lower jaw lengthening.



Two year old with Pierre Robin and severe airway obstruction requiring tracheostomy.



Bilateral mandibular lengthening devices surgically placed with lengthening in progress.



Results after removal of lengthening devices. Patient now ready for removal/closure of tracheostomy.